

Internal impingement in the tennis player: rehabilitation guidelines

A M Cools,¹ G Declercq,² B Cagnie,¹ D Cambier,¹ E Witvrouw¹

¹ Department of Rehabilitation Sciences and Physiotherapy, Faculty of Medicine and Health Sciences, University Hospital, Ghent, Belgium; ² Private Practice, 's Gravenwezel, Belgium

Correspondence to:
Dr A Cools, University Hospital Ghent, Department of Rehabilitation Sciences and Physiotherapy, De Pintelaan 185, 3B3, B9000 Gent, Belgium; ann.cools@ugent.be

Accepted 24 September 2007
Published Online First
7 December 2007

ABSTRACT

Internal impingement is a commonly described cause of shoulder pain in the overhead athlete, particularly in tennis players. Three shoulder dysfunctions, often correlated with internal impingement symptoms, require attention in the rehabilitation strategy of internal impingement in the tennis player: (1) acquired glenohumeral anterior instability, (2) loss of internal rotation range of motion, and (3) lack of retraction strength.

Based on recent literature, the following guidelines are proposed in the rehabilitation of the tennis player with internal impingement symptoms: (1) shoulder rehabilitation should be integrated into kinetic chain training, not only in the advanced phases of the athlete's rehabilitation, but from the initial phases; (2) both angular and translational mobilisations can be used in the treatment of acquired loss of glenohumeral internal rotation range of motion to stretch the posterior structures of the glenohumeral joint; and (3) in the rehabilitation of scapular dyskinesis, the therapist should focus on restoration of intramuscular trapezius muscle balance in the scapular exercises, with special attention to strength training of the retractors.

Chronic shoulder pain is probably the most common arm problem in recreational and competitive overhead athletes.¹⁻⁴ Throwing athletes, athletes involved in racquet sports such as tennis, volleyball players and swimmers need full, unrestricted arm function to optimally perform in their sport.⁵

Non-traumatic shoulder pain in the overhead athlete is a diagnostic challenge. The causes of chronic shoulder pain are numerous, but often difficult to identify and diagnose.⁶⁻¹⁰ Research indicates that shoulder impingement is the most common cause of shoulder pain in overhead athletes.¹¹⁻¹² In recent literature, impingement has been described as a group of symptoms rather than a specific diagnosis. In this current opinion, it is thought that numerous underlying pathologies may cause impingement symptoms. Glenohumeral instability,⁵⁻¹⁵ rotator cuff or biceps pathology,¹³⁻¹⁶ scapular dyskinesis,¹⁴⁻¹⁷⁻¹⁸ and glenohumeral internal rotation deficit¹⁹⁻²¹ have been associated with impingement symptoms in clinical literature. Various anatomical structures can be impinged internally or externally, probably depending on the motion and loading put on the shoulder during the pain-provoking activity.⁷⁻²² However, a possible instability in the shoulder is often "silent" and difficult to show by ordinary tests, and has therefore by some been termed "functional instability". It is now thought that functional instability in the shoulder may lead to a vicious circle involving microtrauma and secondary impingement, and may eventually lead to chronic shoulder pain.²²

Since the first paper, published by Walch²³ *et al*, describing a new site of impingement between the humeral head and the posterosuperior rim of the glenoid, internal impingement has been suggested to be a common cause of chronic shoulder disorder in overhead athletes.²⁴⁻²⁶ This type of impingement occurs in the cocking position of throwing, with the glenohumeral joint in maximal external rotation, maximum horizontal abduction, and, depending on the sport, in abduction or forward flexion. Walch²³ *et al* showed, by performing shoulder arthroscopy with the shoulder placed in 90° of abduction and 90° of external rotation (90/90 position), that the supraspinatus and infraspinatus tendons tend to rotate posteriorly. This more posterior orientation of the tendons aligns them so that they become compressed between the humeral head and the posterosuperior rim of the glenoid. In general, overhead athletes with internal impingement have posterior shoulder pain and tenderness of the infraspinatus tendon on palpation, and are typically athletes intensively active in overhead sports such as tennis.²⁷ Internal impingement particularly occurs when the humeral shaft goes beyond the plane of the body of the scapula during the cocking position of throwing. Under normal circumstances, the scapula goes into retraction simultaneously with the horizontal abduction movement of the humerus. When the body of the scapula and the humeral shaft fail to remain in the same plane of movement during the cocking phase of throwing, encroachment of the rotator-cuff tendons between the humeral head and the glenoid rim may cause internal impingement symptoms. This phenomenon is called "hyperangulation".¹⁹ However, in spite of the documented structural pathology and cuff lesions, shown by several groups to be related to internal impingement symptoms,¹³⁻¹⁹⁻²³ it is suggested that functional disturbances, such as subtle glenohumeral instability, glenohumeral range of motion (ROM) restrictions, scapular dysfunction and muscle stiffness, are often associated with internal impingement symptoms, rather than structural deficits and pathologies.¹⁷⁻²⁸⁻³⁰ These dysfunctions are often the base for conservative treatment, in particular rehabilitation exercises, and need to be considered in the prevention and rehabilitation of shoulder pain in the tennis player.

Numerous studies examining the possible causes and biomechanical backgrounds of internal impingement have been performed. In general, two pathological mechanisms in the possible aetiology of internal impingement have been described: (1) excessive humeral translations, compromising glenohumeral congruence,³¹ and (2) scapular dyskinesis, decreasing the quality of functional scapular stability, and hence jeopardising overhead shoulder function.³⁰

The most commonly described cause of excessive humeral translations is anterior shoulder instability.¹⁰ Overhead athletes very often exhibit acquired glenohumeral instability, characterised by laxity of the anterior capsule, as a result of the extreme use of their shoulder during overhead throwing or smashing activities. This type of acquired instability is often referred to as acquired instability overuse syndrome (AIOS).¹⁰ Several authors have suggested that this type of instability is present in recreational and professional tennis players.^{10 12 32}

A second mechanism related to increased humeral translations is tightness of the posterior structures.^{10 19 30 33} A consistent finding present during examination of overhead athletes is reduced internal rotation ROM of the dominant arm.^{5 19 21 30} Several possible mechanisms have been described to explain the glenohumeral internal rotation deficit (GIRD).^{19 34} The tightness of the posterior capsule and the muscle tendon unit of the posterior rotator cuff is believed to limit internal joint rotation. Burkhart^{19 et al.} defined GIRD as a loss of internal rotation of $\geq 20^\circ$ compared with the contralateral side. When the posterior structures of the glenohumeral joint are shortened, this may compromise the hammock function of the inferior glenohumeral ligament (IGHL), and increase the risk for impingement symptoms during throwing. Under normal circumstances, the IGHL functions as a hammock in the stability of the glenohumeral joint. However, where there is tightness of the posterior band of the IGHL, the humeral head will translate anteriorly, as a result of imbalances between the anterior and posterior band of the IGHL. There is some disagreement about the humeral head movement during the cocking position of throwing or overhead serving in tennis. According to some authors, the posterior band of the IGHL moves inferiorly and slightly anteriorly of the humeral head, thus inducing a posterosuperior translation of the humeral head. This mechanism possibly explains the findings of internal impingement symptoms in the cocking position.¹⁹ During the follow-through phase of throwing, the posterior band of the IGHL is at the posteroinferior side of the humeral head. Tightness in this part of the capsule will induce anterosuperior translations of the humeral head, thus increasing the risk for subacromial impingement. However, other studies³⁵ suggest an anterior and inferior translation of the humeral head during cocking with a tight posterior capsule. As a result, posterior capsule shortness possibly increases internal and subacromial impingement in the overhead athlete.^{19 33 35} Loss of internal rotation ROM in tennis players has been shown by several authors.³⁶⁻³⁸

The treatment goals during the intermediate phase are improvement of functional dynamic stability under circumstances of increasing complexity and specificity, introduction of eccentric exercises and open kinetic chain exercises in preparation for a throwing programme, and strength enhancement of all glenohumeral muscles.²⁷ Informed consent was obtained for publication of this figure.

Besides the glenohumeral component as a possible cause of internal impingement, scapular dyskinesia may play an important role in functional shoulder pain in the overhead athlete.^{17 29} The role of the scapula in normal athletic shoulder function and in shoulder pain in the overhead athlete has been extensively described in the literature.^{18 39} Both clinical experience and scientific data show that athletes with shoulder pathology consistently have abnormalities in scapular rotator activity.^{3 5 28 40 41 42 43} Numerous studies have been published examining muscle activity in the scapular muscles during a variety of movements in athletes involved in overhead activities. Most authors suggest, based on their data, that there are alterations in muscle activity in the upper trapezius (UT), lower trapezius (LT)

and serratus anterior (SA) muscles in patients with symptoms of impingement.^{28 40 41 42 43 44}

During overhead throwing, it is imperative that the scapula can move towards retraction as well as protraction. In the cocking phase, sufficient retraction is necessary to avoid hyperangulation and impingement symptoms.¹⁸ Several studies have shown that overhead athletes have a scapular muscle balance between protractors and retractors slightly <1 , meaning that protractors are stronger than retractors.^{10 40 41} Normal non-athletic subjects have equal strength in their protractors and retractors.⁴⁵ This shift in scapular muscle balance may be the result of sport-specific adaptations; however, a lack of retraction strength may increase the risk for hyperangulation and hence internal impingement.

Therefore, three diagnoses, correlated with internal impingement symptoms, need consideration in the rehabilitation strategy of internal impingement in the tennis player: (1) acquired glenohumeral anterior instability, (2) loss of internal rotation ROM, and (3) lack of retraction strength. These diagnoses are functional disorders rather than structural pathologies, and are probably interrelated to each other. Although cause-effect relationship between these symptoms is not clear, they deserve attention in the prevention and rehabilitation of shoulder pain in the tennis player.

REHABILITATION OF ACQUIRED INSTABILITY

The following description of rehabilitation guidelines for shoulder instability in the overhead athlete is based on clinical literature^{10 14 15 18 27 39 46 47} rather than scientific rationale. It should therefore be taken into account that although numerous authors have described a rehabilitation protocol for shoulder pathology in the overhead athlete, scientific evidence to support the effect of these rehabilitation protocols is scarce. Future investigations should focus on examining the efficacy of these exercise protocols.

The rehabilitation process for overhead athletes with acquired instability must restore muscular balance and muscular endurance, and gradually restore proprioception, dynamic stability and neuromuscular control.^{10 11 24 27} In the initial phase, the major treatment goals are restoration of rotator cuff muscle balance, baseline proprioception and local muscle control.



Figure 1 Closed kinetic chain exercises in the initial stage of shoulder instability rehabilitation.




Figure 2 Initial plyometric exercise: two-hand drill with limited abduction-external rotation of the injured shoulder. Informed consent was obtained for publication of this figure.

In view of the observation that very often the external rotation to internal rotation ratio is reduced in overhead athletes,⁴⁸ special attention should be paid to restoration of muscle control and muscle strength of the external rotators. Closed kinetic exercises are also performed in this phase (fig 1).




Figure 3 Advanced plyometric exercise: one-hand drill with increased abduction-external rotation of the injured shoulder. Informed consent was obtained for publication of this figure.




Figure 4 Kinetic chain integration in closed chain exercises: extending a leg challenges core stability, extension recruitment of leg, and unilateral balance on the other leg. Informed consent was obtained for publication of this figure.

Axial compression exercises stress the joint in a weight-bearing position, resulting in joint approximation and improving co-contraction of the rotator cuff muscles.⁴⁶

The third phase of a functional rehabilitation programme, the advanced phase, is designed to prepare the athlete to return to full athletic activity. Strengthening exercises are continued, and plyometric drills are introduced.⁴⁹ Plyometric exercises consist of quick powerful movements, activating the stretch-shortening cycle of the muscle. Initially the athlete performs the plyometrics using both hands and with the shoulder in a moderate external position (fig 2). Two-hand drills progress to one-hand drills, with increasing velocity and resistance (fig 3).

In recent literature, the role of the kinetic chain has been emphasised in the rehabilitation of the tennis player with shoulder pain.^{17 18 47} The rationale behind the kinetic chain principle is that other body parts, such as the legs or trunk, should be integrated in the shoulder rehabilitation programme, in order to prepare the athlete's whole body, not only the




Figure 5 Kinetic chain integration in commonly used shoulder exercises: shoulder extension combined with squatting. Informed consent was obtained for publication of this figure.



Figure 6 Kinetic chain integration in shoulder diagonals: unilateral balance during diagonal external rotation. Informed consent was obtained for publication of this figure.

shoulder, for the return to athletic activity.^{18 27} Core stability, leg balance, and diagonal movement patterns are examples of facilitation of the kinetic chain into the rehabilitation of the shoulder (figs 4–8). In recent rehabilitation programmes, kinetic chain exercises are prescribed not only in the sport-specific phase of the rehabilitation process, but from the initial phase.²⁷ The specific use of kinetic chain exercises also depends upon the sport the athlete performs: diagonals in prone position may be important for swimming athletes, whereas core stability with minimal leg support may be relevant for the volleyball player. In general, unilateral stance exercises on the non-dominant leg, core stability, and diagonal patterns from the non-dominant leg to the dominant arm can be used in tennis players.^{15 17 18 39 46 47}

REHABILITATION OF GIRD

In general, two types of stretching exercises are described in literature to reduce GIRD^{27 50 51} Angular stretches as well as translational mobilisations are used to increase glenohumeral internal rotation ROM.

In the angular stretching techniques, internal rotation or horizontal adduction movements are passively performed by the therapist or by the patient.^{39 51 52} A popular stretch is the “sleeper’s stretch” (figs 9, 10).^{17 19} The patient’s lies on the injured side with the shoulder in 90° forward flexion. While the scapula is manually fixed into retraction, glenohumeral internal rotation is performed passively, thus stretching the posterior structures of the shoulder. Attention should be paid to the patient’s reaction: a stretching feeling at the back of the shoulder is allowed; however, if the patient feels pain anteriorly, the intensity of the stretching should be reduced by limiting the amount of forward flexion or turning the trunk slightly backwards, thus decreasing the strain on the posterior structures.

In the “cross-body stretch”, the arm is moved into horizontal adduction (figs 11, 12). Recently, Mc Clure⁵² *et al* showed



Figure 7 Kinetic chain integration in shoulder diagonals: core stability during diagonal internal rotation. Informed consent was obtained for publication of this figure.

significantly better results for this stretching technique in increasing the internal rotation ROM compared with the sleeper’s stretch in subjects with restricted internal rotation ROM. However, further research is needed on larger patient populations to confirm these results and to correlate the findings to other clinical features such as pain and symptoms in these patients.



Figure 8 Kinetic chain integration during early plyometric exercises: core stability during shoulder plyometrics. Informed consent was obtained for publication of this figure.



Figure 9 Sleeper's stretch: angular stretching into internal rotation, performed by the therapist. Informed consent was obtained for publication of this figure.

In addition to the angular stretching techniques, translational mobilisation techniques that increase internal rotation ROM have been reported.^{27 53} In order to influence the posterior ligaments, high-grade end-range dorsal-glide mobilisations can be performed. The patient's shoulder is placed in the end range of internal rotation (fig 13) or horizontal adduction (fig 14), and the therapist performs manual translational glides in the dorsal direction. Research indicates that particularly high-grade end-range mobilisations result in a permanent increase in ROM, greater than that achieved with low-grade mid-range mobilisation techniques.^{53 54} However, it should be noted that these investigations were performed on patients with adhesive capsulitis or in cadavers. Moreover, as mentioned earlier, internal impingement may be associated with subtle glenohumeral instability, and GIRD in the tennis player may be present in a potentially unstable shoulder. Therefore, the recommendation of high-grade mobilisations should be interpreted with caution, and its use limited in cases of GIRD without glenohumeral instability.




Figure 10 Sleeper's stretch: angular stretching into internal rotation, performed by the patient. Informed consent was obtained for publication of this figure.



Figure 11 Cross-body stretch: angular stretching into horizontal adduction, performed by the therapist. Informed consent was obtained for publication of this figure.

Little scientific evidence about the effectiveness of these techniques and the possible decrease in internal impingement symptoms is available. Moreover, the literature discusses the causes of GIRD as being stiffness of the posterior capsule or the IGHL, or muscle or bony abnormalities such as retroversion of the humeral head.⁵⁵ Future research should focus on the possible causes of the loss of internal rotation ROM in overhead athletes, as well as on the efficiency of physical therapy techniques.

REHABILITATION OF SCAPULAR DYSKINESIS

In view of the new insights and research findings on the role of the scapula in shoulder pathology, current exercise protocols emphasise the importance of scapular muscle training as an essential component of shoulder rehabilitation.^{6 14 15 17 24 27 39} In particular, restoration of muscle control and balanced coactivation is a challenge to the clinician. For patients with an imbalance in the scapular muscles, selective activation of the weaker muscle parts with minimal activity in the hyperactive muscles is an important component in the reduction of the



Figure 12 Cross-body stretch: angular stretching into horizontal adduction, performed by the patient. Informed consent was obtained for publication of this figure.

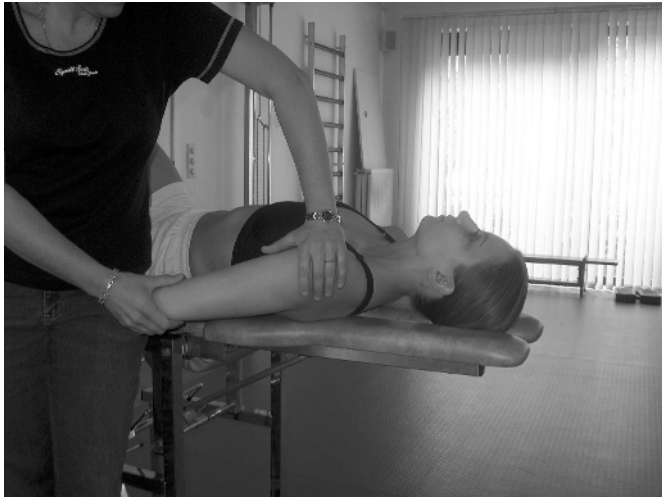

Figure 13 End-range dorsal-glide mobilisations (internal rotation).

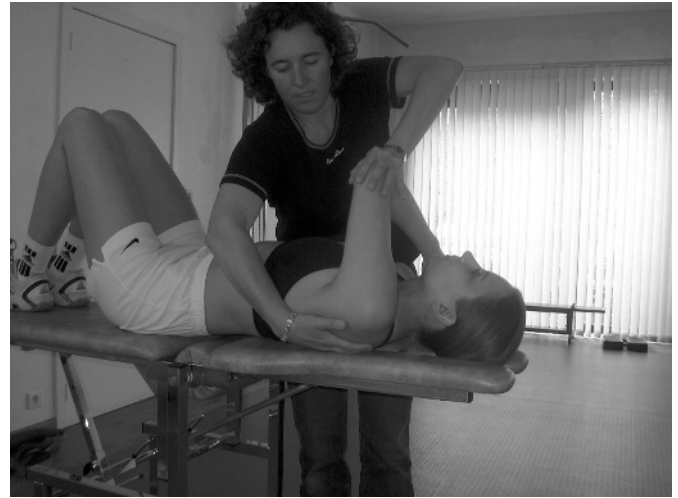

Figure 14 End-range dorsal-glide mobilisations (horizontal adduction).

imbalance. Because a lack of activity in the LT, UT and SA muscles is often combined with excessive use of the UT, the balance ratios UT:LT, UT:MT, and UT:SA are of particular importance.^{28 40–43} In addition, integration of shoulder girdle exercises into a global functional kinetic-chain pattern has become a treatment goal in shoulder rehabilitation, especially in overhead athletes.^{17 18 47}

The selection of appropriate exercises in the rehabilitation of scapular muscle performance depends not only on the actual strength of the muscles, but also on the relative strength of one muscle in relation to another. In a study by Ludewig⁵⁶ *et al*, a selection of exercises was introduced with a low UT:SA ratio, meaning high activity in the SA with simultaneous minimal activation of the UT. However, only UT:SA ratios were examined, and only variations of the push-up exercise were performed.

In a recent investigation,⁵⁷ we identified scapular muscle strengthening exercises in which the LT and middle trapezius (MT) were optimally activated with minimal participation of

the UT. Activity of the UT, MT and LT was analysed using surface electromyography during 12 commonly used scapular exercises, and UT:LT and UT:MT muscle balance ratios were calculated. Four exercises were selected as exercises with a low UT:LT or MT:LT ratio (fig 15): (A) side-lying forward flexion, (B) side-lying external rotation, (C) prone horizontal abduction with external rotation and (D) prone extension in neutral position. As several studies have shown that overhead athletes with impingement symptoms show decreased activity in both LT and MT, with excessive activation of the UT,^{28 40 41 42} these exercises may be used for restoration of both muscle imbalances.

From a clinical viewpoint, the major limitation of these exercises can be found in the outcome itself. Indeed, all the exercises selected based on a low UT:LT or UT:MT ratio are performed in a lying position, prone or side-lying. However, recent literature emphasises the importance of functional exercises, resembling daily or sport specific arm function, and integration of the shoulder rehabilitation into a functional kinetic chain.^{17 18 47}

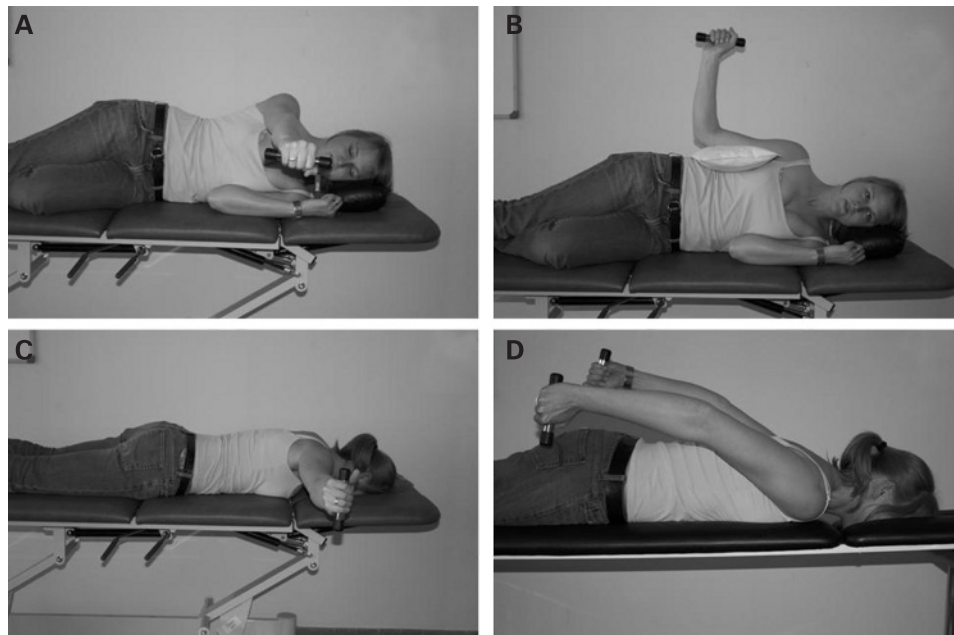


Figure 15 Scapular exercises for restoration of intramuscular trapezius balance.

These treatment goals are very difficult to accomplish with the patient lying down. Diagonal patterns, combined with trunk and lower limb stabilisation, as promoted by a number of authors, are not possible in these exercise techniques. Therefore, we propose that our exercises should be performed in the early stages of rehabilitation, and before more functional kinetic chain exercises, in which functional recruitment patterns can be trained with normalised intermuscular and intramuscular balance ratios.

CONCLUSION

Internal impingement is possibly the result of acquired anterior instability, acquired loss of internal rotation ROM due to posterior shoulder stiffness, and scapular dyskinesis. Before a rehabilitation programme, a thorough physical examination should be performed to define the specific dysfunctions and determine the treatment goals. Physical therapy of acquired instability should focus on integration of the functional kinetic chain in the rehabilitation exercises. Angular stretches and dorsal glide mobilisations may be performed to improve internal rotation ROM; however, the therapist should be cautious in cases with instability. In cases with scapular dyskinesis, restoration of intermuscular and intramuscular muscle balance is the main treatment goal.

Competing interests: None.

Patient consent: Informed consent was obtained for publication of figures 1–12.

REFERENCES

- Almekinders LC. Impingement syndrome. *Clin Sports Med* 2001;**20**:491–504.
- McMaster WC, Troup J. A survey of interfering shoulder pain in United States competitive swimmers. *Am J Sports Med* 1993;**21**:67–70.
- Pink MM, Tibone JE. The painful shoulder in the swimming athlete. *Orthop Clin North Am* 2000;**31**:247–61.
- Tibone JE, Shaffer B. Shoulder pain: when is it impingement? *J Musculo Med* 1995;**12**:65–77.
- Meister K. Injuries to the shoulder in the throwing athlete. Part one: biomechanics/pathophysiology/classification of injury. *Am J Sports Med* 2000;**28**:265–75.
- Bang MD, Deyle GD. Comparison of supervised exercise with and without manual physical therapy for patients with shoulder impingement syndrome. *J Orthop Sports Phys Ther* 2000;**30**:126–37.
- Cavallo RJ, Speer KP. Shoulder instability and impingement in throwing athletes. *Med Sci Sports Exc* 1998;**30**(Suppl):D18–25.
- Meister K. Injuries to the shoulder in the throwing athlete. Part two: evaluation treatment. *Am J Sports Med* 2000;**28**:587–601.
- Neer CS II. Anterior acromioplasty for the chronic impingement syndrome in the shoulder. A preliminary report. *J Bone Joint Surg Am* 1972;**54A**:41–50.
- Wilk KE, Meister K, Andrews JR. Current concepts in the rehabilitation of the overhead throwing athlete. *Am J Sports Med* 2002;**30**:136–151.
- Altchek D, Warren R, Wickiewicz T, et al. Arthroscopic acromioplasty: technique and results. *J Bone Joint Surg Am* 1990;**72A**:1198–207.
- Vanderhoeven H, Kibler WB. Shoulder injuries in tennis players. *Br J Sports Med* 2006;**40**:435–40.
- Jobe C. Superior glenoid impingement. *Clin Orthop* 1996;**330**:98–107.
- Kamkar A, Irrgang J, Whitney S. Non-operative management of secondary shoulder impingement syndrome. *J Orthop Sports Phys Med* 1993;**17**:212–24.
- Kibler B. Shoulder rehabilitation: principles and practice. *Med Sci Sports Exc* 1998;**30**(Suppl):S40–50.
- Morrison DS, Greenbaum BS, Eindhorn A. Shoulder impingement. *Orthop Clin North Am* 2000;**31**:285–93.
- Burkhart S, Morgan C, Kibler W. The disabled shoulder: spectrum of pathology part III: the SICK scapula, scapular dyskinesis, the kinetic chain, and rehabilitation. *Arthroscopy* 2003;**19**:641–61.
- Kibler B. The role of the scapula in athletic shoulder function. *Am J Sports Med* 1998;**26**:325–37.
- Burkhart SS, Morgan CD, Kibler WB. The disabled throwing shoulder: spectrum of pathology: Part I: pathoanatomy and biomechanics. *Arthroscopy* 2003;**19**:404–20.
- Michener LO, McClure PW, Karduna AR. Anatomical and biomechanical mechanisms of subacromial impingement syndrome. *Clin Biomech* 2003;**18**:369–79.
- Warner JJ, Micheli LJ, Arslanian LE, et al. Patterns of flexibility, laxity, and strength in normal shoulders and shoulders with instability and impingement. *Am J Sports Med* 1990;**18**:366–75.
- Sørensen A, Jørgensen U. Secondary impingement in the shoulder. An improved terminology in impingement. *Scand J Med Sci Sports* 2000;**10**:266–78.
- Walch G, Boileau P, Noel E, et al. Impingement of the deep surface of the supraspinatus tendon on the posterolateral glenoid rim: an arthroscopic study. *J Shoulder Elbow Surg* 1992;**1**:238–45.
- Blevins F. Rotator cuff pathology in athletes. *Sports Med* 1997;**24**:205–20.
- Halbrecht J, Tirman P, Atkin D. Internal impingement of the shoulder: comparison of findings between the throwing and non-throwing shoulder of college baseball players. *J Arthroscop Rel Surg* 1999;**15**:253–8.
- Jobe C, Coen MJ, Screner P. Evaluation of impingement syndromes in the overhead-throwing athlete. *J Athl Train* 2000;**35**:293–9.
- Ellenbecker TS, ed. *Shoulder rehabilitation. Non-operative treatment*. New York: Thieme, 2006:180.
- Cools A, Witvrouw E, Declercq G, et al. Scapular muscle recruitment pattern: trapezius muscle latency in overhead athletes with and without impingement symptoms. *Am J Sports Med* 2003;**31**:542–9.
- Laudner KG, Myers JB, Pasquale MR, et al. Scapular dysfunction in throwers with pathologic internal impingement. *J Orthop Sports Phys Ther* 2006;**36**:485–94.
- Myers JB, Laudner KG, Pasquale MR, et al. Glenohumeral range of motion deficits and posterior shoulder tightness in throwers with pathologic internal impingement. *Am J Sports Med* 2006;**34**:385–91.
- Hallstrom E, Karrholm J. Shoulder kinematics in patients with impingement and 12 controls. *Clin Orthop Relat Res* 2006;**448**: 22–7.
- McCann PD, McCann PD, Bigliani LU. Shoulder pain in tennis players. *Sports Med* 1994;**17**:53–64.
- Bigliani LU, Codd TP, Connor PM, et al. Shoulder motion and laxity in the professional baseball player. *Am J Sports Med* 1997;**25**:609–13.
- Bach HG, Goldberg BA. Posterior capsular contracture of the shoulder. *J Am Acad Orthop Surg* 2006;**14**:265–277.
- Huffman GR, Tibone JE, McGarry MH, et al. Path of glenohumeral articulation throughout the rotational range of motion in a thrower's shoulder model. *Am J Sports Med* 2006;**34**:1662–9.
- Ellenbecker TS, Roetert EP, Piorkowski PA, et al. Glenohumeral joint internal and external rotation range of motion in elite junior tennis players. *J Orthop Sports Phys Ther* 1996;**24**:336–41.
- Ellenbecker TS, Roetert EP, Bailie DS, et al. Glenohumeral joint total rotation range of motion in elite tennis players and baseball pitchers. *Med Sci Sports Exerc* 2002;**34**:2052–6.
- Kibler WB, Chandler TJ, Livingston BP, et al. Shoulder range of motion in elite tennis players. Effect of age and years of tournament play. *Am J Sports Med* 1996;**24**:279–85.
- Cools A, Walravens M. *Oefentherapie bij schouderaandoeningen*. Antwerp, Belgium: Standaard Uitgeverij, 2005:213.
- Cools A, Witvrouw E, Declercq G, et al. Evaluation of isokinetic force production and associated muscle activity in the scapular rotators during a protraction-retraction movement in overhead athletes with impingement symptoms. *Br J Sports Med* 2004;**38**:64–8.
- Cools A, Witvrouw E, Mahieu N, et al. Isokinetic scapular muscle performance in overhead athletes with and without impingement symptoms. *J Athl Train* 2005;**40**:104–10.
- Cools AM, Declercq GA, Cambier DC, et al. Trapezius activity and intramuscular balance during isokinetic exercise in overhead athletes with impingement symptoms. *Scand J Med Sci Sports* 2007;**17**:25–33.
- Wadsworth D, Bullock-Saxton J. Recruitment patterns of the scapular rotator muscles in freestyle swimmers with subacromial impingement. *Int J Sports Med* 1997;**18**:618–24.
- Ruwe PA, Pink M, Jobe FW, et al. The normal and the painful shoulders during the breaststroke. Electromyographic and cinematographic analysis of twelve muscles. *Am J Sports Med* 1994;**22**:789–96.
- Cools AM, Witvrouw EE, Danneels LA, et al. Test-retest reproducibility of concentric strength values for shoulder girdle protraction and retraction using the Biodes isokinetic dynamometer. *Isokinetics Exerc Sci* 2002;**10**:129–36.
- Kibler WB. Closed kinetic chain rehabilitation for sports injuries. *Phys Med Rehabil Clin N Am* 2000;**11**:369–84.
- McMullen J, Uhl TL. A kinetic chain approach for shoulder rehabilitation. *J Athl Train* 2000;**35**:329–37.
- Ellenbecker T, Roetert EP. Age specific isokinetic glenohumeral internal and external rotation strength in elite junior tennis players. *J Sci Med Sport* 2003;**6**:63–70.
- Pezzullo DJ. Functional plyometric exercises for the throwing athlete. *Athl Train* 1995;**30**:22–6.
- Johansen RL, Callis M, Potts J, et al. A modified internal rotation stretching technique for overhead and throwing athletes; *J Orthop Sports Phys Ther* 1995;**21**:216–19.
- Lintner D, Mayol M, Uzodinma O, et al. Glenohumeral internal rotation deficits in professional pitchers enrolled in an internal rotation stretching program. *Am J Sports Med* 2007;**35**:617–21.
- Mc Clure P, Balaicuis J, Heiland D, et al. A randomized controlled comparison of stretching procedures for posterior shoulder tightness. *J Orthop Sports Phys Ther* 2007;**37**:108–14.
- Vermeulen HM, Rozing PM, Obermann WR, et al. Comparison of high-grade and lowgrade mobilization techniques in the management of adhesive capsulitis of the shoulder: randomized controlled trial. *Phys Ther* 2006;**86**:355–68.
- Hsu AT, Hedman T, Chang JH, et al. Changes in abduction and rotation range of motion in response to simulated dorsal and ventral translational mobilization of the glenohumeral joint. *Phys Ther* 2002;**82**:544–56.
- Pieper HG. Humeral torsion in the throwing arm of handball players. *Am J Sports Med* 1998;**26**:247–53.
- Ludewig P, Hoff M, Osowski E, et al. Relative balance of serratus anterior and upper trapezius muscle activity during push-up exercises. *Am J Sports Med* 2004;**32**:484–93.
- Cools AM, Dewitte V, Lanszweert F, et al. Rehabilitation of scapular muscle balance: which exercises to prescribe? *Am J Sports Medicine* 2007;**35**:1744–51.



Internal impingement in the tennis player: rehabilitation guidelines

A M Cools, G Declercq, B Cagnie, et al.

Br J Sports Med 2008 42: 165-171 originally published online December 10, 2007

doi: 10.1136/bjsem.2007.036830

Updated information and services can be found at:
<http://bjsm.bmj.com/content/42/3/165.full.html>

These include:

References

This article cites 55 articles, 20 of which can be accessed free at:
<http://bjsm.bmj.com/content/42/3/165.full.html#ref-list-1>

Article cited in:

<http://bjsm.bmj.com/content/42/3/165.full.html#related-urls>

Email alerting service

Receive free email alerts when new articles cite this article. Sign up in the box at the top right corner of the online article.

Topic Collections

Articles on similar topics can be found in the following collections

[Degenerative joint disease](#) (128 articles)
[Musculoskeletal syndromes](#) (263 articles)

Notes

To request permissions go to:

<http://group.bmj.com/group/rights-licensing/permissions>

To order reprints go to:

<http://journals.bmj.com/cgi/reprintform>

To subscribe to BMJ go to:

<http://group.bmj.com/subscribe/>